



# Managing Blunt Trauma–Induced Hemoperitoneum in Dogs and Cats

Arathi Vinayak, DVM

D. J. Krahwinkel, DVM, MS, DACVS, DACVA, DACVECC

University of Tennessee

## ABSTRACT:

Hemoperitoneum is a common sequela following blunt abdominal trauma. Treatment includes medical and surgical options. Physical examination findings alone should not be used to decide to pursue medical management instead of surgery. Options for medical management include initial stabilization of the respiratory and cardiovascular systems, diagnostic imaging, diagnostics such as paracentesis or diagnostic peritoneal lavage, cessation of hemorrhage, and homologous blood or blood-substitute transfusions or autotransfusions. Surgery should be reserved for patients that cannot be stabilized despite aggressive medical intervention.

In veterinary patients, trauma and neoplasia have been recognized as the two most common causes of hemoperitoneum.<sup>1</sup> Hemoperitoneum, the abnormal accumulation of blood in the peritoneal cavity, can be a fatal sequela to trauma. Vehicular trauma has reportedly caused intraabdominal injury in 6.3% to 13% of injured animals.<sup>2</sup> However, the true prevalence of hemoperitoneum after blunt vehicular trauma is unknown and has been difficult to evaluate because of insidious onset, variability of clinical signs, and time required before an adequate volume of blood can accumulate for identification by diagnostic peritoneal lavage or abdominal paracentesis. Blunt trauma to the spleen and liver can involve a delay of up to 3 hours or more before signs of shock develop.<sup>3</sup> Blunt trauma to the liver, spleen, kidneys, and major vessels can cause hemorrhage in patients. The liver and spleen are thought to be the most likely sources of severe, ongoing hemorrhage.<sup>4</sup> Because of its large size, fri-

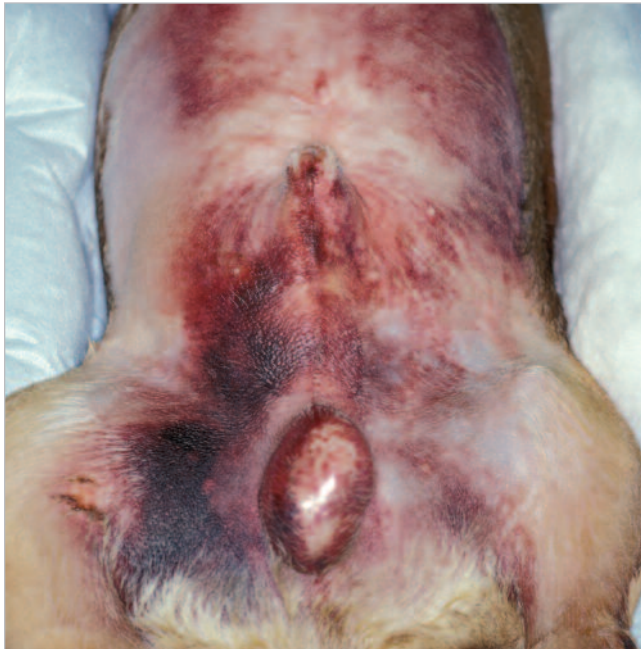ability, and relative immobility, the liver has reportedly been the most commonly injured intraabdominal organ.<sup>2,5</sup>

Controversy exists as to whether a patient with hemoperitoneum should be managed medically or surgically. In humans, most intraabdominal solid-organ injuries are treated without operative therapy, and surgery is reserved for patients that are hemodynamically unstable.<sup>6</sup> It is now proposed that aggressive medical therapy should be initiated to stabilize veterinary patients and abdominal exploration should be reserved for those that continue to deteriorate despite medical intervention.<sup>1,4,5</sup> Clinical presentation, stabilization, diagnostics, and options for medical management of hemoperitoneum due to blunt abdominal trauma are discussed in this article. In addition, indications for operative management of hemodynamically unstable patients are described.

## CLINICAL PRESENTATION

On presentation of a dog with apparent or known blunt trauma, the patient should be rap-

Email comments/questions to [compendium@medimedia.com](mailto:compendium@medimedia.com), fax 800-556-3288, or log on to [www.VetLearn.com](http://www.VetLearn.com)



**Figure 1.** Bruising on the abdomen of a dog with a history of blunt abdominal trauma.

idly assessed and initial fluid restoration initiated. A complete history and thorough physical examination can be done once the patient has been stabilized.<sup>7</sup> Pertinent information to obtain while taking a history includes the nature of the trauma, when the incident occurred, and progression of clinical signs since the traumatic incident. Owners should also be questioned about the animal's mental status since the accident; amount of external blood loss; ability to ambulate; and status regarding vomiting, dyspnea, urination, and defecation. A thorough history allows emergency diagnostics to be targeted to the injury site and provides an overall assessment of an animal.

A complete physical examination should be performed because signs of abdominal hemorrhage may not have been detected in the initial rapid evaluation. Physical examination findings might include abdominal tenderness or distention, bruising of the abdomen or hemorrhage around the umbilicus (Figure 1), or presence of a fluid wave on abdominal ballottement.<sup>1</sup> The circular discolorations around the umbilicus seen in about 10% of patients with marked intraabdominal hemorrhage are due to diapedesis of erythrocytes into subcutaneous tissues.<sup>4,8</sup> At least 40 ml/kg of blood must be present before abdominal distention can be detected.<sup>9</sup> However, a diagnosis of hemoperitoneum cannot be made based

solely on physical examination findings. Although physical findings may be suggestive of abdominal injury, results from one study indicate that only six of 17 patients (35.3%) exhibited physical signs that had serious visceral disruption confirmed at surgery or necropsy.<sup>10</sup> In other words, physical examination findings included 10 false-negative results (58.8%) and one false-positive result (5.9%). Similar findings were reported in a human study in which 43% of 437 patients with blunt trauma had no signs or complaints suggestive of intra-abdominal injury.<sup>11</sup> Forty-four percent of these patients were ultimately explored, and 77% of them had injury requiring surgical repair. Thus it can be surmised that physical findings alone are unreliable in assessing severity of intraabdominal injury.

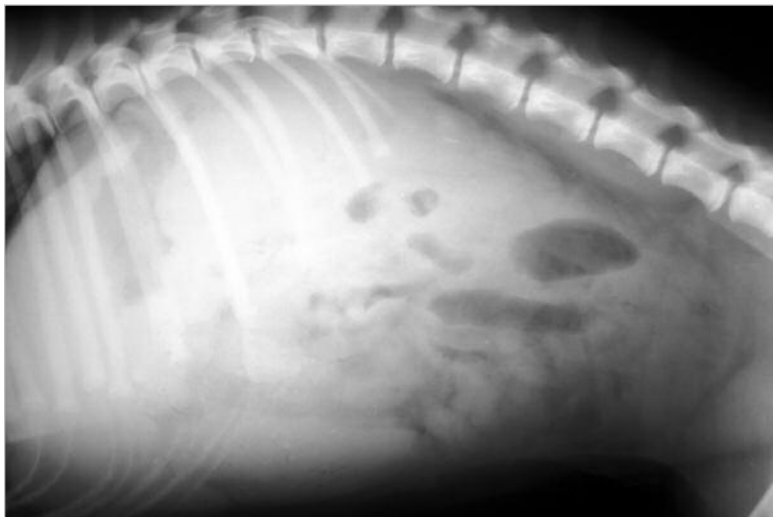
## INITIAL STABILIZATION AND DIAGNOSTICS

The primary consideration in any animal with a history of blunt trauma should be to identify life-threatening problems that require immediate attention.<sup>12,13</sup> A brief history and rapid evaluation of vital signs are essential before embarking on initial treatment. Clinical signs of intraabdominal hemorrhage can range from severe hemorrhagic shock and death to virtually undetectable findings on physical examination. When present, clinical signs are usually caused by hypovolemic shock (i.e., tachypnea, tachycardia, decreased central venous pressure, impaired peripheral perfusion). Presence of a patent airway and adequate ventilation should be confirmed by observing thoracic excursions and confirming air movement by auscultation.<sup>1</sup> Circulation should be initially assessed by palpating pulses, evaluating mucous membrane color, and determining capillary refill time. A brief but thorough examination of the cardiovascular, respiratory, central nervous, and renal systems usually identifies problems that require prompt stabilization.<sup>13</sup>

Oxygen therapy (e.g., delivered by a nasal catheter, mask, transtracheal catheter) should be considered to maximize tissue oxygenation. Circulatory support to maintain tissue perfusion is usually required in cases of intraabdominal hemorrhage. A large-bore central or peripheral catheter should be placed for immediate IV fluid therapy. Before fluid therapy, whole-blood samples should be collected for a serum chemistry profile, a complete blood cell count (including a blood coagulation profile), and an arterial/venous blood gas analysis, whenever possible.<sup>1,13</sup> A urine sample should be collected for urinalysis as part of the minimum database.

Ideally, dogs should be blood typed and cross-matched to be sure the donor and recipient are compatible, especially if previous blood transfusions have been given. In an emergency in which blood typing is not possible, blood from a donor that tests negative for dog erythrocyte antigen 1.1 can be used for dogs with no history of blood transfusions. All cats should be blood typed or crossmatched (as a means of typing) before a blood transfusion because there is a risk of fatal reactions when non-type-specific blood is given.

With acute blood loss into the abdomen, the intravascular space initially becomes depleted. Replenishing intravascular volume should be the primary goal in stabilization because it takes time for extravascular fluids to enter the intravascular space to increase blood volume and restore perfusion. Isotonic crystalloid fluids should be administered at two or three times the perceived volume of intravascular loss because crystalloid fluids equilibrate between the intravascular and extravascular spaces.<sup>14</sup> Because it may be difficult to estimate the volume of losses, isotonic crystalloids can be administered IV as rapidly as possible at shock doses of 60 to 90 ml/kg



**Figure 2.** Lateral abdominal radiograph of a dog with severe hemorrhagic abdominal effusion as evidenced by lack of serosal detail and a “ground-glass” appearance.

bleeding in patients with blunt trauma. Computed tomography (CT) is used routinely in humans with blunt trauma but has yet to gain popularity in veterinary medicine.<sup>6</sup> Abdominal radiography and ultrasonography are the most commonly employed imaging modalities

## ***Insidious onset of clinical signs and variable progression of hemoperitoneum may make diagnosis difficult in some animals with a history of blunt trauma.***

in dogs and 45 to 60 ml/kg in cats. Because there is a risk of fluid overload, caution should be exercised in patients that are cardiovascularly compromised or have a pulmonary injury. Initial crystalloid fluid type (e.g., lactated Ringer’s solution, normal saline, sodium chloride) and rate of infusion should be based on perceived deficits and then adapted to the individual animal. Subsequent alterations to the fluid therapy regimen can be made based on results of hematology and serum chemistry values. Colloidal fluid support (e.g., dextran, hetastarch, plasma) should be considered in cases with ongoing hemorrhage or hemodilution due to crystalloid therapy.

### **DIAGNOSIS**

Following stabilization, imaging is an important modality in the diagnostic plan to identify sources of

for confirming the presence of abdominal fluid and to locate the intraabdominal source of hemorrhage. Follow-up diagnostics to provide immediate identification of suspected abdominal hemorrhage based on results of imaging include paracentesis (needle or catheter), diagnostic peritoneal lavage, and ultrasound-guided aspiration of abdominal fluid.

### **Imaging Radiography**

Before using invasive diagnostics such as abdominocentesis, abdominal radiography should be considered a first-line diagnostic test in stable trauma patients with suspected abdominal effusion.<sup>15,16</sup> Inadvertent introduction of air into the peritoneal cavity (i.e., iatrogenic pneumoperitoneum) by paracentesis techniques can

cause confusion as to whether air was present before the procedure because of rupture of a hollow viscus. Radiographic findings suggestive of effusion include focal or generalized loss of serosal detail, which creates a “ground-glass” effect on radiographs (Figure 2). Thoracic radiography should also be conducted in all trauma patients to rule out rib fractures, diaphragmatic hernia, pneumothorax, or pulmonary contusions indicative of thoracic trauma.<sup>13</sup> Patients with diaphragmatic hernia and respiratory distress are not candidates for external abdominal counterpressure.<sup>17</sup>

### **Abdominal Ultrasonography**

Abdominal ultrasonography has been used to identify and guide aspiration of free abdominal fluid and affords the added advantage of possibly identifying abnormalities of the abdominal organs, abdominal wall, or diaphragm.<sup>1,13</sup> In a recent study evaluating a focused abdominal sonogram for trauma (FAST) protocol to identify free abdominal fluid following blunt abdominal trauma, transverse and longitudinal views were obtained in four locations with dogs placed in left lateral recumbency (i.e., just caudal to the xiphoid process, on midline over the bladder, and over the most gravity-dependent area of the right or left flank).<sup>18</sup> Of 100 dogs evaluated within 24 hours of trauma by emergency room clinicians with minimal sonographic experience, 45 were diagnosed with free abdominal fluid. Abdominal paracentesis was performed in 40 of these dogs, and hemoperitoneum was confirmed in 38 dogs and uroabdomen in two. An overall sensitivity of 96% and a specificity of 100% were reported, making this a simple and effective diagnostic tool for identifying free abdominal fluid in blunt trauma cases.

### **Computed Tomography**

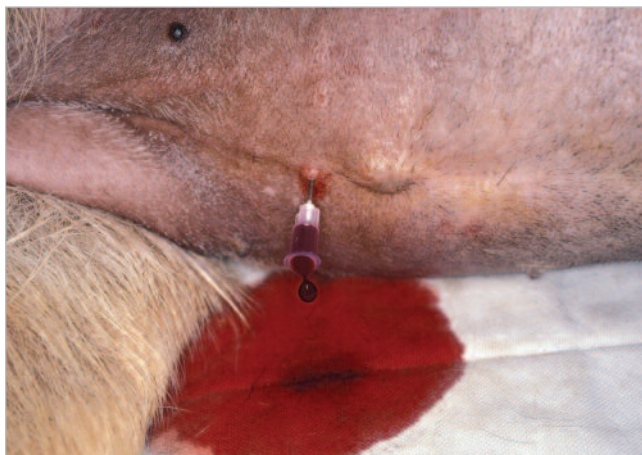CT can be used to estimate the amount of intraabdominal hemorrhage and to grade the severity of solid-organ injury in human trauma cases. Delayed bleeding from liver trauma is uncommon, but delayed rupture of the spleen and continued retroperitoneal hemorrhage from renal injury are common occurrences.<sup>6</sup> Repeat CT helps to eliminate these delayed phenomena. Expense, limited access, and the need for general anesthesia limit the use of CT as an imaging modality in cases of blunt trauma in veterinary medicine.

### **Confirmation of Abdominal Hemorrhage**

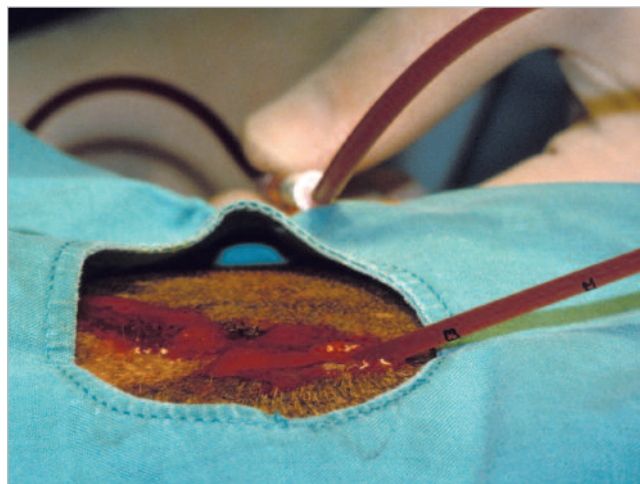
#### **Abdominal Paracentesis and Lavage (Needle Versus Catheter)**

Analysis of abdominal fluid is considered the definitive way to diagnose hemoperitoneum in veterinary patients. Abdominal paracentesis or lavage is indicated in any dog with a history of blunt trauma in conjunction with shock, multiple injuries, or signs of abdominal injury.<sup>19</sup> Conventional retrieval of abdominal fluid has included simple and four-quadrant needle paracentesis. Simple open-needle paracentesis involves insertion of a 20- to 22-gauge needle at the level of the umbilicus without the syringe attached, with the patient in either lateral or dorsal recumbency<sup>15</sup> (Figure 3). If fluid is not obtained, the needle can be gently repositioned. If fluid is still not obtained, a 3- to 6-ml syringe can be attached and mild negative pressure applied (i.e., a closed technique). Four-quadrant needle paracentesis should be performed in a manner similar to simple paracentesis, with the exception that needle placement involves using the





**Figure 3.** Simple open-needle paracentesis performed with a 20-gauge, 1.5-inch needle at the level of the umbilicus, illustrating the presence of nonclotting free blood characteristic of hemoperitoneum.



**Figure 4.** Diagnostic peritoneal lavage performed with warm sterile isotonic fluid (20 ml/kg) in a dog with blunt trauma–induced hemoperitoneum.

right cranial, left cranial, right caudal, and left caudal quadrants centered around the umbilicus.<sup>10,20</sup>

If fluid cannot be obtained with either open- or closed-needle paracentesis, diagnostic abdominal paracentesis using either a peritoneal dialysis catheter<sup>10,19</sup> or a 16- to 20-gauge, 1.5- to 2-inch over-the-needle catheter<sup>15</sup> can be performed using techniques similar to

techniques do not provide a diagnostic sample.<sup>15</sup> Diagnostic peritoneal lavage should be performed with the animal in lateral recumbency. A 10 × 10-cm area centered around the umbilicus on the ventral abdomen should be aseptically prepared. A 16- to 20-gauge over-the-needle catheter or a peritoneal lavage catheter should be inserted caudal to the umbilicus after local anesthetic

## ***The liver and spleen are the most likely sources of severe, ongoing intraabdominal hemorrhage secondary to blunt trauma.***

those described in humans.<sup>19</sup> For this method, the urinary bladder must be catheterized and emptied to avoid iatrogenic puncture. With the patient in lateral recumbency, a local anesthetic should be infiltrated 1 to 2 cm caudal to the umbilicus. The catheter should be inserted and directed caudally toward the dependent areas of the abdomen. Directing the catheter in this direction decreases the chance of injury to the spleen, liver, or pancreas and reduces the chance of obstructing the catheter with omentum.<sup>19</sup> Fluid that flows freely should be collected. If fluid does not flow, the catheter can be repositioned or the dog gently rolled to the opposite side to facilitate collection.

Alternatively, diagnostic peritoneal lavage can be performed when simple and four-quadrant paracentesis

infiltration as already described. An IV line attached to a fluid bag containing a calculated volume of sterile, warmed isotonic fluid (10 to 20 ml/kg) should be connected to the catheter and fluid rapidly infused over 2 to 5 minutes into the abdominal cavity.<sup>15</sup> After the calculated volume has been administered, the patient should be gently rolled or the abdomen massaged to disperse the fluid. Fluid should be recovered from the abdominal catheter by placing the fluid bag in a dependent position relative to the patient for gravity-assisted fluid collection (Figure 4). Up to half the lavage volume may be retrieved in this manner for analysis.

In one study involving 17 patients, hemoperitoneum was diagnosed in one patient with serious intraabdominal injuries using four-quadrant needle paracentesis, in

seven patients using dialysis catheter paracentesis alone, and in 14 patients when lavage was combined with dialysis catheter paracentesis.<sup>10</sup> Accuracies as low as 47.3% have been reported in diagnosing hemoperitoneum with needle paracentesis techniques compared with 82.9% when using a catheter alone and 94.6% with diagnostic peritoneal lavage.<sup>16</sup> Another study reported 100% accuracy in detecting hemoperitoneum in blunt trauma cases with a catheter technique and 62% accuracy with needle paracentesis.<sup>19</sup> In laboratory studies, the number of patients diagnosed with hemoperitoneum using a needle paracentesis technique increased proportionally to the volume of blood infused into the abdomen.<sup>10</sup> A minimum fluid volume of 5 to 6 ml/kg must be present for a positive tap with a needle paracentesis technique,<sup>15</sup> whereas volumes as low as 1 to 4.4 ml/kg for dialysis catheter paracentesis<sup>19</sup> and 0.8 ml/kg for a catheter and lavage combination have been reported.<sup>10</sup> The increased sensitivity with catheter paracentesis can be attributed to the larger diameter of the catheter and the presence of numerous side holes that increase surface area for contact with abdominal fluid.<sup>19</sup>

### **Ultrasound-Guided Paracentesis**

In veterinary patients with blunt trauma, the FAST protocol shows promise in detecting free fluid and guiding aspiration of free fluid in the abdomen.<sup>18</sup> Although ultrasonography is a rapid and noninvasive diagnostic test in humans, its use has been limited in veterinary medicine by lack of availability in some private practices.

### **Clinicopathologic Testing of Abdominal Fluid**

Fluid samples from the abdomen should be analyzed for creatinine, total protein, amylase, lipase, glucose, potassium, bilirubin, hematocrit, pH, PaO<sub>2</sub>, and carbon dioxide levels based on clinical suspicion.<sup>15,21–23</sup> Biochemistry results aid in diagnosing injury to the liver, biliary tract, spleen, intestines, kidneys, ureters, urinary bladder, and urethra.<sup>15</sup> Cytology of a direct smear and centrifuged sediment should be evaluated for bacteria, inflammatory cells, and vegetable fibers. When only a small quantity of fluid can be obtained, cytology has reportedly been the most valuable test.<sup>13</sup> Bloody fluid from abdominal paracentesis should be evaluated grossly for clotting. A diagnosis of hemoperitoneum can be made when blood in the fluid does not clot and cell counts (erythrocytes and leukocytes), creatinine levels, and amylase activity are similar to those in circulating blood. Accidental splenic aspirate in a volume-repleted

patient<sup>15</sup> or fluid shifts in a hypotensive patient must be considered when the hematocrit level of the effluent is higher than that of peripheral blood. Unintentional aspiration from the spleen and other abdominal organs or vessels can be differentiated because the blood sample clots unless there is underlying coagulopathy.<sup>1,13</sup> A packed cell volume greater than 2% to 5% in abdominal fluid obtained with diagnostic peritoneal lavage indicates significant hemorrhage.<sup>24</sup>

### **MEDICAL MANAGEMENT OF INTRAABDOMINAL HEMORRHAGE**

Once hemoperitoneum has been diagnosed, attempts to arrest and manage abdominal hemorrhage should follow. Circumferential external counterpressure, homologous blood or blood-substitute transfusion, autotransfusion, and internal counterpressure have shown efficacy in both experimental and clinical settings. However, because all of these methods may be associated with complications, the pros and cons of each method should be considered, and the final decision regarding the best method to employ should be made on a case-by-case basis.

### **Circumferential External Counterpressure**

Pressure can be applied to the ventral abdomen by wrapping a cotton roll in layers from the xiphoid to the pubis.<sup>4,25</sup> The cranial end of the pillow should be thicker to improve compression under the rib cage. An elastic bandage should then be applied to compress the cotton (Figure 5). Care should be taken to exclude the caudal rib margin from the wrap because severe and immediate respiratory distress was noted in one study when the bandage included this area.<sup>25</sup> External abdominal counterpressure elevates intraabdominal pressure above systolic pressure at the hemorrhaging site, thereby limiting hemorrhage.<sup>25,26</sup>

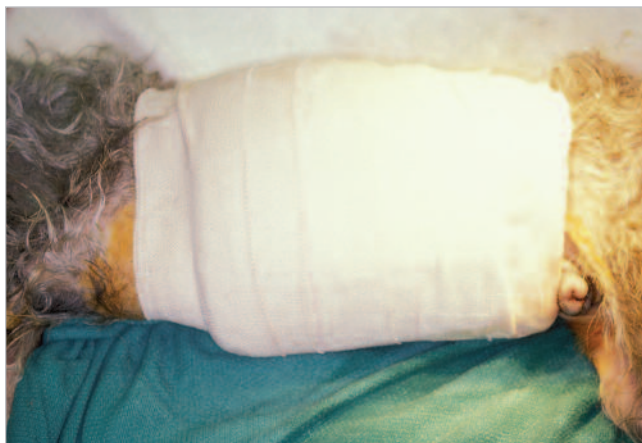One laboratory study evaluating circumferential external counterpressure by abdominal wraps in dogs with induced intraabdominal hemorrhage showed that compressive bandaging limited the decline in mean arterial pressure (MAP), slowed or stopped hemorrhage, and increased survival time compared with results in hemorrhaging unbandaged control dogs.<sup>25</sup> Changes in pulmonary arterial pressure, pulmonary capillary wedge pressure, and cardiac index were not statistically different between bandaged and unbandaged dogs.

---

## ***Patients that are stable on presentation or stabilize after fluid resuscitation should be considered candidates for nonoperative management.***

---

The decrease in magnitude of fall in MAP results from increased total peripheral resistance (which increases MAP in conjunction with an essentially unchanged cardiac output) and a tamponade effect that limits blood loss. External counterpressure can also temporarily increase systemic arterial blood pressure and central venous pressure, thereby increasing cardiac output and blood flow to the myocardium and brain.<sup>27</sup> External counterpressure is not a benign procedure and may be associated with serious consequences if applied incorrectly or for longer than recommended. Also, lethal effects are possible if there is undiagnosed thoracic injury such as a diaphragmatic hernia.<sup>24</sup> Normal intraarticular pressures (IAPs) as high as 7.5 cm H<sub>2</sub>O have been determined.<sup>26</sup> Applying an external circumferential bandage increased IAP to an average of 19.11 cm H<sub>2</sub>O immediately after application, and IAP averaged 45.58 ± 9.55 cm H<sub>2</sub>O when the bandage was removed 2 hours later.<sup>25</sup> IAP exceeding 27 cm H<sub>2</sub>O can produce renal failure, hypoxemia, and cardiovascular abnormalities (i.e., changes in heart rate, arterial blood pressure, and central venous pressure).<sup>25,28,29</sup> IAP has been measured in the abdominal vena cava by catheterizing the femoral vein<sup>25</sup> or connecting a transurethral Foley catheter to a water manometer.<sup>26</sup> In a clinical setting, it may be difficult to determine the force being applied by counterpressure. To avoid excessive and potentially harmful pressure, it is recommended that the wrap be loose enough to permit placement of one finger between the abdomen and bandage.<sup>27</sup>



**Figure 5.** External abdominal counterpressure to arrest intraabdominal hemorrhage in a dog.

Staged release of the bandage every few minutes is recommended once vital signs, blood pressure, and pulse pressures have been stabilized because abrupt removal of the wrap has been shown to decrease MAP.<sup>25</sup> MAP should be measured during staged wrap removal to avoid a decrease in systemic arterial blood pressure of more than 5 mm Hg, which could lead to life-threatening hypotension.<sup>27</sup> If systemic blood pressure decreases more than 5 mm Hg, staged removal should be discontinued temporarily and aggressive IV fluid replacement instituted until hemodynamic stabilization can be achieved. Ideally, the following variables should be monitored approximately every 5 minutes when using external counterpressure: heart rate, respiratory rate and effort, hematocrit, total protein level, oxygen saturation, MAP, IAP, and urine output.<sup>25,26,28,29</sup>

### Homologous Blood Transfusion

The decision to transfuse should be based on assessment of clinical signs of anemia (e.g., tachycardia, respiratory distress, poor pulse quality) because there is no set hematocrit value at which transfusion should be required. A rapid decline in hematocrit can quickly produce clinical disease, whereas animals with chronic blood loss can tolerate a lower hematocrit value and exhibit minimal clinical signs. Use of blood or blood substitute products is usually considered after an attempt to replace intravascular losses with crystalloid and/or colloid fluids. Factors to consider when deciding whether to administer a transfusion include volume of blood loss, rapidity of loss, nature of ongoing losses, and patient condition. Veterinary patients with acute mas-

sive hemorrhage resulting in a hematocrit value lower than 20% and an albumin concentration less than 2.0 g/dl should undergo transfusion to maintain erythrocyte mass for adequate tissue perfusion and oxygenation.<sup>30</sup> Similar recommendations have been made in humans, such that transfusions are performed in cases of acute blood loss and when the hematocrit is lower than 25%.<sup>31</sup>

In an ideal situation, crossmatch results from a peripheral blood sample taken before fluid therapy aid in donor selection. Fresh or stored whole blood and packed erythrocytes are options in patients that require intravascular volume expansion in addition to oxygen-carrying support.<sup>14</sup> The goal should be to increase the hematocrit to more than 25% and albumin concentration to more than 2 g/dl. Advantages of fresh whole blood (i.e., blood stored less than 8 hours after collection) are that it provides erythrocytes, leukocytes, platelets, plasma proteins, and coagulation factors; however, availability poses a problem for many veterinarians.

Stored whole blood (i.e., blood stored longer than 8 hours after collection) provides erythrocytes, plasma proteins, and some coagulation factors. Disadvantages include loss of platelet function and decreased labile coagulation factor concentration after 24 hours of storage. Administering packed erythrocytes is the treatment of choice in cases of massive hemorrhage because they increase erythrocyte cell mass more rapidly, thereby increasing peripheral tissue oxygenation.

Alternatively, hemoglobin-based oxygen-carrying solution (i.e., Oxyglobin, Biopure) can be used when blood products are unavailable.<sup>32</sup> Although erythrocyte mass remains unchanged, Oxyglobin can be given as a bolus, exerts a colloidal oncotic pressure to help maintain intravascular volume, and is more efficient than erythrocytes in releasing oxygen. The recommended dose for treating hemorrhage is 15 to 30 ml/kg, not to exceed 10 ml/kg/hr in dogs or 5 ml/kg/hr in cats. The half-life of Oxyglobin is 30 to 40 hours; it is metabolized and excreted 5 to 7 days after administration. This product is useful for the immediate situation; however, use of blood products may have to be considered for long-term management.

### Autotransfusion

Before infusing blood from a body cavity back into a patient's circulation, a clinicopathologic analysis of abdominal fluid should be conducted to ensure that autotransfused blood is not contaminated with urine from a ruptured bladder or ingesta from a gastrointestinal tract rupture. Because it may be difficult to obtain



adequate quantities of stored homologous blood or to find suitable blood donors, autotransfusion should be considered in patients with ongoing intraabdominal hemorrhage. Advantages of autotransfusion include lack of transmission of blood-borne diseases (e.g., hemobartonellosis, toxoplasmosis, babesiosis, feline leukemia), no risk of isoimmunization to cellular antigens, and prompt availability of compatible blood for critical patients.<sup>33</sup> Autotransfused blood usually requires anticoagulation unless blood has remained in contact with peritoneal surfaces for longer than 45 minutes, resulting in platelet destruction and defibrination. The two anticoagulants most commonly used for this purpose include heparin at 30 to 50 units per 60 ml of blood collected<sup>33</sup> and acid citrate dextrose at 1 ml per 7 ml of blood collected.<sup>4</sup>

Complications that can arise with large-volume autotransfusions include fat microembolization, lipoprotein denaturation, and cellular microaggregation, which could lead to acute pulmonary failure and disseminated intravascular coagulopathy (DIC).<sup>4,33</sup> Also, autotransfused blood is very low in platelets and clotting factors and may, therefore, prolong hemorrhage.<sup>4</sup> Thus autotransfused blood must be filtered using a micropore filter, and an anticoagulant must be added. Low-dose heparin (100 U/kg SC q8h) has been

recommended to help prevent DIC; this dosage is thought to be low enough to not interfere with coagulation and cause additional hemorrhage. It would be wise, however, to monitor activated clotting times for effects of heparin (i.e., activated clotting time should remain within normal limits unless the patient is already experiencing DIC).<sup>4</sup>

### **Internal Counterpressure**

Internal counterpressure can be applied with 22 ml/kg of warmed lactated Ringer's solution infused into the abdomen for a tamponade effect to arrest intraabdominal hemorrhage. In one study, this method was shown to be most efficacious when lavage had already been performed.<sup>4</sup> There are no recent studies evaluating the benefits, risks, and efficacy of internal counterpressure in cases of intraabdominal hemorrhage. Therefore, its current clinical application is unknown.

### **SURGICAL EXPLORATION AND CORRECTION**

In a retrospective study of 28 cases of severe hemoperitoneum due to blunt trauma, a survival rate of 67% was reported in patients managed surgically after minimal medical management versus a rate of 75% in

patients managed medically.<sup>5</sup> However, these survival rates were not statistically different. Systemic and effusion hematocrit, peripheral pulse rate, site of hemorrhage, and age did not predict survival or the decision to perform surgery. The study did find that larger animals had a better prognosis for survival with surgery. Mortality rates as high as 70% to 100% have been reported in cases of severe intraabdominal hemorrhage that were not managed surgically.<sup>34</sup> However, no concrete guidelines exist to help clinicians choose between medical versus surgical management.

Several suggestions have been made as to when surgery should be considered, including after serial abdominal ultrasonographic examinations showing increased volume of abdominal effusion,<sup>1</sup> serial abdominal fluid analyses showing active bleeding (i.e., continued rise in effluent hematocrit),<sup>5</sup> and an unstable response to fluid and blood administration.<sup>1,5</sup> In addition, surgical exploration is recommended in humans when transfusion requirements exceed 20 ml/kg, which is approximately 28% to 30% of blood volume.<sup>31</sup> Studies evaluating the significance of these suggestions in veterinary medicine have not been conducted, and the final decision for surgical intervention should primarily be made based on experience, cost:benefit ratio, and the inability to stabilize a patient with medical intervention.

## REFERENCES

- Brockman DJ, Mongil CM, Aronson LR, et al: A practical approach to hemoperitoneum in the dog and cat. *Vet Clin North Am Small Anim Pract* 30:657–668, 2000.
- Kolata RJ, Johnson DE: Motor vehicle accidents in urban dogs: A study of 600 cases. *JAVMA* 167:938–941, 1975.
- Fossum TW: Surgery of the abdominal cavity, in Fossum TW (ed): *Small Animal Surgery*. St. Louis, Mosby, 1997, pp 179–199.
- Crowe DT: The steps to arresting abdominal hemorrhage. *Vet Med* 83: 676–677, 680–681, 1988.
- Mongil CM, Drobatz KJ, Hendricks JC: Traumatic hemoperitoneum in 28 cases: A retrospective review. *JAAHA* 31:217–222, 1995.
- Knudson MM, Maull KI: Nonoperative management of solid organ injuries. *Surg Clin North Am* 6:1357–1371, 1999.
- Crane SW: Evaluation and management of abdominal trauma in the dog and cat. *Vet Clin North Am Small Anim Pract* 10:655–689, 1980.
- Crowe DT, Todoroff RJ: Umbilical masses and discolorations as signs of intraabdominal disease: 1 cat and 4 dogs. *JAAHA* 18:295–298, 1982.
- Gfeller RW: An intensivist's approach to hemoabdomen. *Proc ACVIM* 20:14–16, 2002.
- Crowe DT, Crane SW: Diagnostic abdominal paracentesis and lavage in the evaluation of abdominal injuries in dogs and cats: Clinical and experimental investigations. *JAVMA* 168:700–705, 1976.
- Davis JJ, Cohn I, Nance FC: Diagnosis and management of blunt abdominal trauma. *Ann Surg* 183:672, 1976.
- Stone JL: Evaluation and immediate management of the trauma patient. *Canine Pract* 2:19–24, 1975.
- Walters PC: Approach to the acute abdomen. *Clin Tech Small Anim Pract* 15:63–69, 2000.
- Oakley D: Massive blood loss: Management and transfusion support. *Proc Intern Vet Emerg Crit Care Symp*:755–756, 2000.
- Walters MJ: Abdominal paracentesis and diagnostic peritoneal lavage. *Clin Tech Small Anim Pract* 18:32–38, 2003.
- Crowe DT: Diagnostic abdominal paracentesis techniques: Clinical evaluation in 129 dogs and cats. *JAAHA* 20:223–230, 1984.
- Maull KI, Krahwinkel DJ, Rozycki GS, et al: Cardiopulmonary effects of the pneumatic anti-shock garment on swine with diaphragmatic hernia. *Surg Gynecol Obstet* 162:17–23, 1986.
- Boysen SR, Rozanski EA, Tidwell AS, et al: Focused abdominal sonogram for trauma (FAST) in 100 dogs [abstract]. *Proc Intern Vet Emerg Crit Care Symp*:765, 2003.
- Kolata RJ: Diagnostic abdominal paracentesis and lavage: Experimental and clinical evaluations in the dog. *JAVMA* 168:697–699, 1976.
- Gill W, Champion HR, Long WB, et al: Abdominal lavage in blunt trauma. *Br J Surg* 62:121–124, 1975.
- Rubin MJ, Bland WH, Stanistic TH, et al: Diagnosis of intraperitoneal extravasation of urine by peritoneal lavage. *Ann Emerg Med* 14:91–95, 1985.
- Schmeidt C, Tobias KM, Otto CM: Evaluation of abdominal fluid: Peripheral blood creatinine and potassium ratios for diagnosis of uroperitoneum in dogs. *J Vet Emerg Crit Care Soc* 11:275–280, 2001.
- Swann H, Hughes D, Drobatz KJ: Use of abdominal fluid pH, pO<sub>2</sub>, pCO<sub>2</sub>, [glucose] and [lactate] to differentiate bacterial peritonitis from non-bacterial causes of abdominal effusion in dogs and cats [abstract]. *J Vet Emerg Crit Care Soc* 6:2, 2000.
- Dye T: The acute abdomen: A surgeon's approach to diagnosis and treatment. *Clin Tech Small Anim Pract* 18:53–65, 2003.
- McAnulty JF, Smith GK: Circumferential external counterpressure by abdominal wrapping and its effect on simulated intra-abdominal hemor-

- rhage. *Vet Surg* 15:270–274, 1986.
26. Conzemius MG, Sammarco JL, Holt DE, et al: Clinical determination of preoperative and postoperative intra-abdominal pressures in dogs. *Vet Surg* 24:195–201, 1995.
  27. Crowe DT: Counterpressure use in shock and hemorrhage, in Bonagura JD, Kirk RW (eds): *Kirk's Current Veterinary Therapy XII*. Philadelphia, WB Saunders, 1995, pp 147–149.
  28. Shenasky JH, Gillenwater JY: The renal hemodynamic and functional effects of external counterpressure. *Surg Gynecol Obstet* 134:253–258, 1972.
  29. Barnes GE, Laine GA, Giam PY, et al: Cardiovascular responses to elevation of intra-abdominal hydrostatic pressure. *Am J Physiol* 248:208–213, 1985.
  30. Kirby R, Rudloff E: Fluid and electrolyte therapy, in Ettinger SJ, Feldman EC (eds): *Textbook of Veterinary Internal Medicine*. Philadelphia, WB Saunders, 2000, pp 325–347.
  31. Shackford SR, Molin M: Management of splenic injuries. *Surg Clin North Am* 70(3):595–620, 1990.
  32. Day TK: Case studies on the clinical use of hemoglobin-based oxygen-carrying solutions. *Proc Intern Vet Emerg Crit Care Symp*:161–169, 2000.
  33. Crowe DT: Autotransfusion in the trauma patient. *Vet Clin North Am Small Anim Pract* 10:581–597, 1980.
  34. Crowe DT: Emergency surgery of the hemoabdomen. *Proc Intern Vet Emerg Crit Care Symp*:562–566, 2000.

## ARTICLE #2 CE TEST



This article qualifies for 1.5 contact hours of continuing education credit from the Auburn University College of Veterinary Medicine. Subscribers who wish to apply this credit to fulfill state relicensure requirements should consult their respective state authorities regarding the applicability of this program. To participate, fill out the test form inserted at the end of this issue.

### 1. The most likely source(s) of severe ongoing intra-abdominal hemorrhage in blunt trauma patients is(are) the

- a. peritoneum and abdominal wall.
- b. liver and spleen.
- c. pancreas.
- d. gallbladder and biliary tract.
- e. bladder and urethra.

### 2. The first step in managing a hemodynamically unstable patient with hemoperitoneum is

- a. obtaining a history.
- b. imaging to identify the source of hemorrhage.
- c. paracentesis to diagnose abdominal hemorrhage.
- d. confirming airway patency and instituting circulatory support.
- e. arresting hemorrhage with internal or external abdominal counterpressure.

### 3. Which of the following is the least valuable in diagnosing hemoabdomen in veterinary patients?

- a. visualizing fluid via ultrasonography
- b. CT
- c. obtaining a sample for paracentesis or ultrasound-guided aspiration
- d. abdominal bruising and tenderness on palpation
- e. abdominal radiography

### 4. Gross and clinicopathologic examination of the fluid sample confirms clinical suspicion of hemo-peritoneum when

- a. bloody fluid clots immediately after sampling.
- b. the fluid is more viscous than peripheral blood.

- c. the creatinine concentration of the sample exceeds that of peripheral blood, indicating an intact urinary system.
- d. nonclotting blood with cell counts (erythrocyte and leukocyte) and creatinine and amylase concentrations similar to peripheral blood are obtained.
- e. the hematocrit of the sample exceeds that of peripheral blood hematocrit in a volume-repleted patient.

### 5. IAP exceeding 27 cm H<sub>2</sub>O when using external abdominal counterpressure can compromise \_\_\_\_\_ function.

- a. renal
- b. cardiovascular
- c. pulmonary
- d. a and b
- e. a, b, and c

### 6. Which of the following is not an advantage to using hemoglobin-based products in cases with massive intraabdominal hemorrhage?

- a. ability to dose a bolus, which cannot be done with blood products
- b. exerting colloidal oncotic pressure to help maintain intravascular volume
- c. increased erythrocyte mass and long-term management
- d. releasing oxygen more readily than with erythrocytes
- e. no need for crossmatching, and safe use in cases with a history of transfusion

### 7. Autotransfusion is a procedure in which

- a. hemorrhage from a body cavity is infused back into a patient's circulation following filtration.
- b. blood collected from a different species is transfused into a patient following filtration.

- c. blood from a member of the same species is transfused into a patient following a crossmatch and filtration.
- d. blood from a patient's circulation is infused into the patient's abdomen for intraperitoneal absorption.
- e. hemoglobin-based products, such as Oxyglobin, are transfused.

#### **8. Disadvantages of autotransfusion include**

- a. fat microembolization, lipoprotein denaturation, and cellular aggregation.
- b. acute pulmonary failure and DIC.
- c. a very low platelet count resulting from platelet destruction.
- d. a low concentration of clotting factors.
- e. all of the above

#### **9. In a stable patient or patient stabilized with circulatory support,**

- a. four-quadrant needle paracentesis should be used after taking a history and performing a thorough physical examination.
- b. radiographs should be obtained before invasive diag-

nostics to avoid iatrogenic pneumoperitoneum that may interfere with accurate radiographic interpretation.

- c. simple needle paracentesis, which is most accurate in detecting the presence of abdominal fluid, should be performed.
- d. ultrasound-guided paracentesis should be performed to detect fluid as well as damage to intraabdominal organs.
- e. the patient can be placed under observation in an intensive care setting with no further diagnostic workup.

#### **10. Indications for surgical exploration and correction in traumatic hemoperitoneum include**

- a. increased volume of abdominal effusion on serial ultrasonographic examinations despite medical intervention.
- b. severe abdominal bruising and pain on initial physical examination.
- c. continued increase in effluent hematocrit and hemodynamic instability despite aggressive medical management.
- d. a and b
- e. a and c